
The Fatal Case of Lyssavirus Encephalitis in the Russian Far East

Galina N. Leonova, Larisa M. Somova,
Sergei I. Belikov, Il'ya G. Kondratov,
Natalya G. Plekhova, Natalya V. Krylova,
Elena V. Pavlenko, Mikhail P. Tiunov and
Sergey E. Tkachev

Additional information is available at the end of the chapter

<http://dx.doi.org/10.5772/52869>

1. Introduction

Lyssaviruses represent the Lissavirus genus belonging to the family Rhabdoviridae [Warrell, Warrell, 2004]. This genus includes 7 genotypes. Genotype 1 is Rabies virus, which is widespread all over the world [Hughes, 2008; Iseni et al., 1998]. Genotypes 2 (Lagos bat virus) [Boulger, Porterfield, 1958; Sureau et al., 1980], 3 (Mokola virus) [Shope et al., 1970; Familusi et al., 1972; Kemp et al., 1972] and 4 (Duvenhage virus) [Meredith et al., 1971; Van der Merwe, 1982] are widespread in Central and South Africa. In European countries as well as in European part of Russia there are European bat lyssaviruses of subtypes 1 and 2 (EBLV-1 и EBLV-2) belonging to genotypes 5 and 6, which were isolated from bats and humans bitten by them (for EBLV-1: [Boulger, Porterfield, 1958; Schneider, Cox, 1994; Selimov et al., 1989; Selimov et al., 1991], for EBLV-2: [Lumio et al., 1986; King et al., 1994]). Australian bat lyssavirus (ABLV) belongs to genotype 7, which is also known to be isolated from humans [McCall et al., 2000; Fraser et al., 1996]. Four genotypes have been recently discovered which are Aravan Virus (Kyrgyzstan) [Botvinkin et al., 1996; Kuzmin et al., 1992], Khujand virus (Tajikistan) [Kuzmin et al., 2001], Irkut virus (Eastern Siberia) and West Caucasian Bat virus (Caucasus) [Botvinkin et al., 2003].

The risk of bat virus infection in humans is low. Every three months the single cases of chiropteran and human virus infection are reported in Europe (France, Spain, Slovenia, Germany, Romania, Ukraine, Russia, etc.) [Rab. Bull. Europe, 2008]. The confirmed cases of rabies

following the bat bite were reported in Ukraine and Russia [Botvinkin et al., 2005]. These cases were associated with European bat virus type 1 (EBLV-1). Human cases of Lyssavirus infection in Siberia and Russian Far East were undiscovered so far.

This paper reviews the epidemiological and clinico-morphological characteristics of the fatal human case of not previously described lyssavirus infection identified in Asian Russia as well as results of virological and molecular genetic analysis of its infection agent.

2. Methods of diagnosis

2.1. Virological tests

The brain samples taken postmortem from the patient were used to prepare 10% suspension. To isolate the virus two-day-old noninbred white mice were used. These animals were challenged with 0.01 ml of 10% brain suspension both intracerebrally and subcutaneously. The isolated strain was called Ozernoe after the place where the dead patient was infected.

The titer of virus with 10-fold dilution was determined using intracerebral inoculation of the two-day-old and three-week-old white mice as well as pig embryo kidney (PEK) cell cultures.

2.2. Immunological methods

The IgG antibodies were determined by ELISA using a Vector-TBE-IgG kit ("Vector-Best", Novosibirsk, Russia). We used the conventional methods for determine hemagglutinating properties of the isolated strain and haemagglutination-inhibition (HI) antibodies in the patient's blood.

For the indirect immunofluorescent (IF) antibody method Ozernoe strain was used to infect continuous PEK cell culture; the slides were prepared on the second day after infection. The luminescent sera against human globulins (manufactured by Gamaleya Institute of Epidemiology and Microbiology RAMS, Moscow, Russia) were used to detect the specific luminescence of the antigen-antibody complexes. The titer of specific antibodies was determined by the bright green intraplasma granular fluorescence of the specific complex using the end-point dilutions of the blood serum.

2.3. Morphological methods

Conventional methods were used for pathohistological examination of the cadaveric material fixed in 8% neutral buffered formalin. The samples were fixed in paraffin wax according to the standard technique [Pearse, 1968], and sections with five micron thickness were cut using a hand-driven microtome and transferred to egg albumin coated slides. Then the sections were dewaxed in xylene, stained in hematoxylin and eosin, mounted in DPX, and viewed under light microscope and photographed (Axioscope A1, Zeiss, Germany).

2.4. Electron Microscopy (EM)

The passaged PEK cell culture was infected with Ozernoe strain. After one day the monolayer was separated from the glass using 0.2 ml of 0.25% trypsin solution after each removal of supernatant fluid for 5 minutes. The PEK cells (2×10^6), after infection for 1, 2 and 3 days with Ozernoe virus strain, were placed into the combined fixator for 1 h at room temperature [Ito, Karnovsky, 1968]. The fixator was prepared on the basis of 0.2 M cacodylate buffer (pH 7.4) with 3% paraformaldehyde and 0.02% picric acid. After centrifugation the cells were postfixed in 1% buffered OsO₄ (Serva, USA) at room temperature for 2 hours. Later on, the dehydration of samples was performed in ethanol solution of increasing density and embedded in epon-araldite resin (Serva, USA). The ultra thin microscopic sections were prepared with ultramicrotome LKB-V (LKB, Sweden) in a plane parallel to the cells monolayer. Samples were contrasted with lead citrate by standard method and examined with Libra 200 FE (Carl Zeiss, Germany) transmission electron microscope.

2.5. Molecular genetic methods

2.5.1. Extraction of RNA, PCR and sequencing

Total RNA was extracted from the brain of infected suckling mice using a RIBO-zol-A kit (AmpliSens, Russia) according to the manufacturer's protocol. Reverse transcription reaction was carried out using random hexanucleotide primers and Reverta-L-10 kit (InterLabService, Russia) according to the manufacturer's recommendations. For initial detection of virus we used primers previously described by Heaton et al. (1997) for nucleoprotein-encoding genes with minor modifications (JW12 – ATGTAACACCCCTACAATGG, JW6(DPL) – CAATTTGCACACATTTTGTG, JW6(M) – CAGTTAGCGCACATCTTATG, JW6(E) – CAGTTGGCACACATCTTGTG). Amplification was performed with common forward primer JW12 and one of the backward primers (JW6(DPL), JW6(M), JW6(E)) alternately. The length of amplification product of the lyssavirus nucleoprotein gene fragment was equally 605 bp. The set of primers for complete genome sequencing has been constructed on the basis of full genome sequence of strain Irkut (GeneBank Accession EF614260), so the amplified fragments were 600-700 nucleotides in length, and overlapping areas of the adjacent fragments were 70-100 nucleotides in length. PCR was carried out in the final volume of 20 µl. PCR buffer contained 4.0 – 6.0 mM magnesium chloride, 65 mM Tris-HCl (pH 8.8), 20 mM (NH₄)₂SO₄, 0.01% Tween-20, 200 mM of each dNTP, 0.5 units of Taq-polymerase (AmpliSens, Russia), 10 pmol of each primer and 0.5 – 2 µl of cDNA mixture (template). The amplification was performed with DNA Engine Dyad (MJ Research, USA) using initial denaturation at 96°C for 30 sec followed by 35 cycles of amplification (5 sec – 96°C, 5 sec – 53°C, 1 min – 72°C). All PCR products were analyzed in 0.8 % agarose gel in TAE buffer contained ethidium bromide and DNA amplicons were extracted from gel slices with QIAquick gel extraction kit (Qiagen). In purified PCR products the both strands were directly sequenced using the same set of primers. Sequencing was performed with Genome Lab DTCS-Quick Start Kit (Beckman Coulter, USA) and automated sequencer CEQ-8800 (Beckman Coulter, USA).

2.5.2. *Phylogenetic analysis*

Phylogenetic trees were constructed by: (i) maximum-parsimony (MP) using algorithms from the DNAPARS and PROTPARS programs of the PHYLIP package; (ii) neighbour-joining (NJ) using the evolutionary distance correction statistics of Kimura (1980) and Tajima & Nei (1984); and (iii) maximum-likelihood (ML) using the PAUP* phylogenetic program [Swofford, 2001].

Bootstrap resampling analysis [Felsenstein, 1985] was carried out using 1000 data replications to evaluate the robustness of the phylogenetic groupings observed. Bootstrap values gave a strong evidence for a particular phylogenetic grouping [Hillis, Bull, 1993]. All ABL nucleotide sequences obtained in this study have been submitted to GeneBank and their accession numbers are listed in Table 1. All other lyssavirus nucleotide sequences used for phylogenetic analysis and sequence comparison were obtained from GenBank; their accession numbers and appropriate references are listed in Table 1.

3. The results of a comprehensive study of virus infection case

3.1. Clinical and epidemiological diagnosis

The patient was a twenty-year-old girl named Zh. who was the resident of Ozernoye village (Yaroslavy Region, Primorye Territory, Far East of Russia). She's got an acute disease on the 10th of September, 2007 (medical record No11063). The epidemiological anamnesis contained two facts to be paid attention to. Firstly, on July 12 – 13, 2007 the patient was bitten by a tick into lumbar region while being in forest zone of Yaroslavy Region. Prior to this, she had been vaccinated against tick-borne encephalitis (TBE) and had routine revaccinations. Secondly, on August 10, 2007 in Ozernoe the girl ran into the bat which entered into the house. Being frightened by a loud music the bat has bumped into the girl and wounded her underlip left two thin parallel slightly bleeding stripes. The bat species was unknown. The wounds healed in a short period of time. During one month the girl's mother who was a health-care worker, did not notice any inflammatory infiltration in the wound or increase of regional lymph nodes. The girl felt well and did not have any complaints. She was not vaccinated against rabies.

One month later (on September 10, 2007) the girl got an acute disease caused by hypothermia (she sopped in the rain). Her body temperature rose up to 38°C and intensive headache, repeated vomiting, diplopia, head and hand tremor occurred. On September 11, 2007 she was hospitalized to infectious disease ward of Ussuriysk hospital. The patient has got worse: the general brain symptomatology (constricting diffuse headache and multiple vomiting without any relief) and toxic syndrome increased (the body temperature reached 38.6°); the photophobia occurred. The bulbar disturbances (choking when swallowing, baryphonia) added and increased; profuse discharge of phlegm from the upper respiratory tract was noticed; meningeal symptoms and depression of consciousness (soporific state) occurred. On September 13, 2007, the patient with a diagnosis of meningoencephalitis was tak-

en into the Primorye Clinical Hospital No.1 of Vladivostok. On her arrival at hospital department of resuscitation and intensive care the patient was in deep sopor. She was found to have three-finger stiff neck. Kernig's sign was not observed. Pupils with the diameter of 3 mm were sluggish in respond to the light, D<S. The diagnosis set was infectious (virus) meningoencephalitis of unknown origin, an acute stage with a severe course attended by deep flaccid paresis and bulbar syndrome. On September 14, 2007, the patient was examined by a neurologist who indicated poor general state and depressed consciousness up to the level of superficial coma. The skin of arms, legs and upper shoulder girdle was covered with punctulated hemorrhagic rash (D=1–1,5 mm). There was Kernig's sign of 160° – 170° on both sides. Pupils were mydriatic, D=S; pupillary reactions were lively. Amyotonia of limbs was observed. Deep reflexes were very weak, D=S; pathological reflexes were not recorded. An assumption of rhabdovirus infection was made upon epidemiological anamnesis, presence of hemorrhagic rash on the skin, ecchymoses at sites of injection, bloody vagina discharges, hypersalivation, and neurologic symptomatology, as well as lack of vaccination against rabies. Development of infection was probably caused by abrupt hypothermia.

As seen in Tabl. 1, blood test revealed the decrease in hemoglobin level (from 149.7 g/L to 116.7 g/L), erythrocyte content (from 4.9×10^9 cells per liter to 3.5×10^9 cells per liter), the hematocrit (from 48 to 32) and increase in erythrocyte sedimentation rate (ESR) (from 20 mm/hr to 65 mm/hr). At all times a stable leukocytosis ($10 - 13 \times 10^9$ cells per liter) was observed. To estimate a degree of neutrophil shift in blood which reflects the severity of pathologic process, an index of neutrophil shift, which normally is 0.06, was counted. On arrival of the patient at hospital department the index of neutrophil shift was 0.2 that is 3.3 times higher than normal. At the day when patient died the index of neutrophil shift was 0.4, that is 6.7 times higher than normal. The value of leukocyte intoxication index (LII) by Calf-Ca-liph is representative for the estimation of an intoxication degree. Normally, the LII is 0.3 – 1.5 units and the values ≥ 1.5 indicate the intoxication. After the hospitalization of the patient the LII was 3.8 units, and by the time of death it was 8.3 units indicating the high stage of intoxication.

| Parameters | 13.09.2007 | 21.09.2007 |
|--|----------------------------|----------------------------|
| Hemoglobin | 149,7 g/l | 116,7 g/l |
| Erythrocytes | $4,9 \cdot 10^9$ cells/l | $3,5 \cdot 10^9$ cells/l |
| Hematocrit | 48 | 32 |
| ESR | 20 mm/h | 65 mm/h |
| Leukocytes | $10-13 \cdot 10^9$ cells/l | $10-13 \cdot 10^9$ cells/l |
| (DNI) delta neutrophil index (normal - 0.06) | 0,2 | 0,4 |
| (LI) Leukocyte index of intoxication (normal - 0,3-1,5 u.) | 3,8 u. | 8,3 u. (high toxicity) |

Table 1. Dynamics of the hematological parameters.

Moreover, the determination of total serum immunoglobulin levels (IgM, IgG, IgA) in the patient's blood (on the arrival at hospital) showed the dis-immunoglobulinemia with IgM level 2.4 times higher than normal (3.15 g/L and 1.30 g/L, respectively), and IgG and IgA levels 1.5 and 1.8 times, respectively, lower than normal. The number of circulating immune complexes (CIC) of small sizes was 1.7 times higher than normal (123 and 72 arbitrary units, respectively). The results of hematomanaly indicated increasing intensity of intoxication, overall inflammatory reaction, and multiple organ failure.

Despite the intensive therapy (antibacterial, antiviral, neurometabolic, symptomatic, and artificial lung ventilation (ALV) via bronchostomy) the patient was getting worse every day due to the increase of general brain symptoms coupled with multiple organ failure, bilateral hypostatic pneumonia, arterial blood pressure (ABP) fall up to 60/40 mm Hg, and apparent tachycardia of 140 – 160 beats per minute. On the eleventh day, September 21, 2007, the disease resulted in fatal outcome.

3.2. Pathologic diagnosis

The pathologic diagnosis was an acute stage of meningoencephalitis as an underlying disease with complications of edema, swelling and dislocation of brain as well as bilateral hypostatic pneumonia and parenchymatous degeneration of myocardium, liver and kidney. The post-mortem analysis indicated an acute spongy edema in brain and hemocirculatory disorders in all parts of the central nervous system (CNS) (Fig. 1). A significant vascular disruption of the microvasculature was due to plethora, fibrinoid necrosis of vascular wall and the presence of fibrin in the vascular lumen (1 a, b, c), as well as erythrocytosis (1 d), hyaline thrombi (1 f) and a small amount of mononuclear cells in many vascular lumen. Around some lumen a sparse perivascular lymphohistiocytic infiltrate was observed (1 a). The spongy edema was found in all parts of the brain. It was the mostly evident in the cerebellum with fiber dissociation of the medullary substance; also the small diapedetic hemorrhages were found. In the cerebellar cortex a total loss of Purkinje cells was observed without any evident proliferation of Bergmann glia. Besides, a dramatic depletion and atrophy of granular layer was found. The mild proliferating and infiltrating components of inflammation stood out particularly due to severe destructive changes of the inflammatory process structure in the CNS. Along with the vascular disruption a total chromatolysis and necrobiosis of nerve cells were found, as well as the formation of many neuronophagic nodules like "rabies nodules" mainly in the subcortical brain (Fig. 1g). In the lung a vascular plethora, erythrocytosis, red thrombi in vascular lumen, destructive changes of many vascular walls and an evident serohemorrhagic edema of pulmonary tissue were presented. A polymorphic cellular exudate was observed in the lumen of some large bronchi. In the lung parenchyma a damage of alveolar septa followed by formation of emphysematous areas filled with serofibrinous contents were found. A focal inflammatory polymorphic cellular infiltration was observed. In the spleen the pathohistological changes characterizing a severe immunodeficiency state as delymphatization of white pulp follicles which were not almost visualized were found. At the same time, lymphocyte aggregations were identified only in periarteriolar follicular area (T-dependent zone). A cellular depletion with nonuniform tissue atrophy and denudation of stroma were observed in red pulp. Also the vascular plethora, erythrocytosis, fibrinoid swelling, fibrinoid necrosis and hyalinosis of

vascular walls, as well as thickening and hyalinosis of septa were found. In the liver the extended dystrophic and necrobiotic changes of parenchyma coupled with diffuse sparse proliferation of Kupffer cells and friable polymorphic cellular infiltration along the portal tracts followed by destruction of blood vessel walls were presented. In the kidney a severe necrotic glomerulonephrosis was found. In the cortical substance a necrosis and destruction of the vessels in malpighian tufts, as well as hemorrhages were observed. In the medullary substance a vascular plethora and hemorrhages were found. Also a total necrobiosis and tubular epithelium necrosis were observed along the nephrons. The results obtained by histological study indicated the severe multipleorgan pathology coupled with systemic destructive-dystrophic changes of blood vessels with predominance of edematous and destructive changes in CNS and parenchymatous organs. The pathological process was accompanied by the development of a severe immunodeficiency and a suppression of cell-mediated inflammatory response.

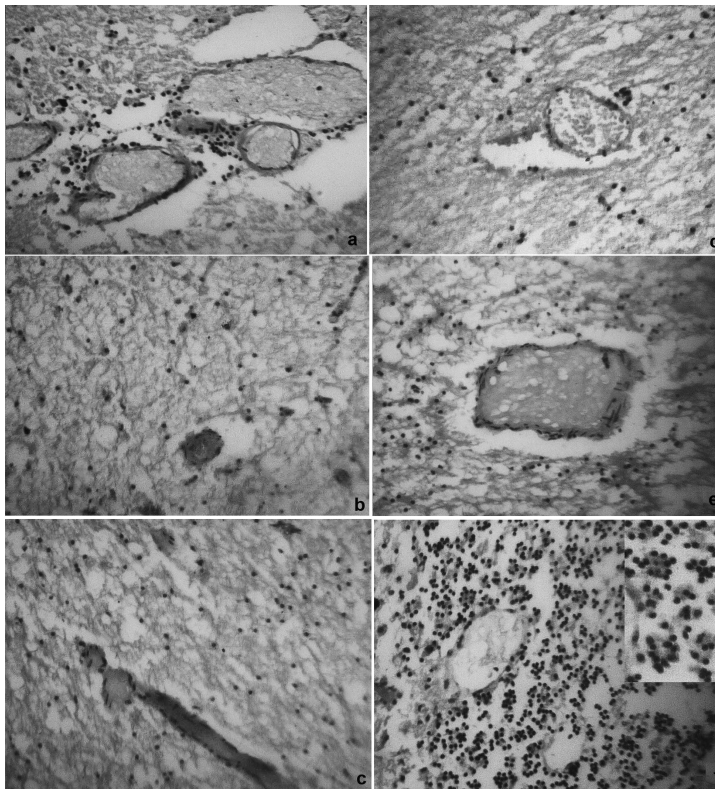


Figure 1. The pathomorphological changes in brain of patient Zh. deceased because of Lyssavirus infection. A – a sparse perivascular found round some lumen; B, C – lymphohistiocytic infiltrate significant vascular disruption of the microvasculature with the fibrinoid necrosis of vascular wall and the presence of fibrin in the vascular lumen; D – erythrocytosis; E – hyaline thrombi and a small amount of mononuclear cells in many vascular lumen; F – neuronophagic nodules like "rabies nodules" in the subcortical brain. Gemotoxiline-eozine; X 200.

3.3. The laboratory diagnostics

The brain samples taken postmortem were used to prepare 10% suspension for the infection of two-day-old noninbred white mice. All mice have fall ill on the seventh day; and during the reisolation the symptoms appeared on the sixth day (physical inactivity and respiratory impairment followed by death) (Fig. 2). With the first passage the incubation period shortened to 5 – 6 days.

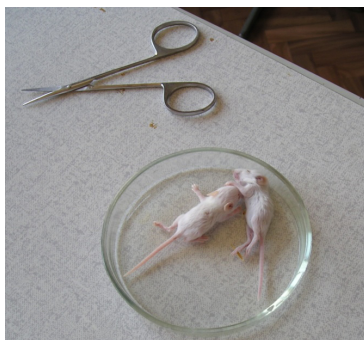

Figure 2. The clinical picture of infection for 6-7 days in mice infected with a 10% suspension of the brain of dead patient Zh.

The two-day-old white mice challenged intracerebrally showed high susceptibility to the isolated virus. Its titer content in the brain of the dead patient was 3.7 lg LD₅₀, and on the first passage it has reached 6.0 lg LD₅₀. At the same time, the susceptibility of the three-four-week-old white mice was much lower; in the first passage the virus titre has hardly reached 2.5 lgLD₅₀. The virus antigen showed an evident hemagglutinating activity; in the brain of the dead patient it was 32 a.u., and in the brain on the suckling mice it was 64-128 a.u. The isolated virus strain was named Ozernoe, and the conclusion about the virus etiology of disease was made.

On the fourth day after the onset of disease the patient blood was tested by ELISA for antibodies against tick-borne encephalitis virus (TBEV) and borrelia because the anamnesis had the fact of tick bite in the endemic part of Primorskiy region. The IgM class antibodies against both pathogens were not found, but IgG antibodies against TBEV were revealed with titer 1:800 that was estimated as antibodies after earlier anti-TBEV vaccination. The hemagglutinating antigen was obtained from the brains of infected mice and used in hemagglutination-inhibition reaction test (HIRT); in this test the homologous antibodies were revealed in patient blood sera with titer 1:20. But belonging of this antigen to the particular virus wasn't known, so PEK cells cultures were infected with Ozernoe strain and then the slides with antigen were prepared for virus identification by indirect immunofluorescence test (IIFT). To get the evidence of homologous antigen specificity in IIFT the blood sera of patient Zh. was used. Both in HIRT and in IIFT the titer were low (the titer 1:40 by specific fluorescence in IIFT). Moreover, the blood serum of person triple-immunized against rabies

virus was used for antigen detection in IIFT. Using the slides with Ozernoe strain antigen the antibodies with titer 1:160 were found in this blood serum that could indicate the close antigen relationship between studied strain and vaccine strain of rabies virus. Based on the obtained data we considered that this fatal case could be prevented with timely course of vaccine prophylaxis against rabies virus.

3.4. Electron Microscopy (EM)

The electron microscopy study revealed that the cytoplasm of infected PEK cells contained multivesicular and lamellar bodies. The granular electron-dense structures with fibrillar inclusions were observed around of the cellular nucleus or very close to the plasma membrane during all periods of infection. The number of these structures increased with time and a larger number of them were found at 72 h post-infection (Figs 3b). The granular electron-dense structures were localized very close to the plasma membrane or fused to it (Figs 3c). Each infected cell contained from 2 to 8 cytoplasmic inclusions which seemed to be Negri body-like (viral ribonucleoprotein (RNP)) structures as a strongly electron-dense matrix. The assembled viral particles with 100 nm in diameter and variable lengths (approximately 670 nm) were observed around such structures (Figs 3d). The viral particles were also associated with vesicles close to the endoplasmic reticulum or Golgi apparatus.

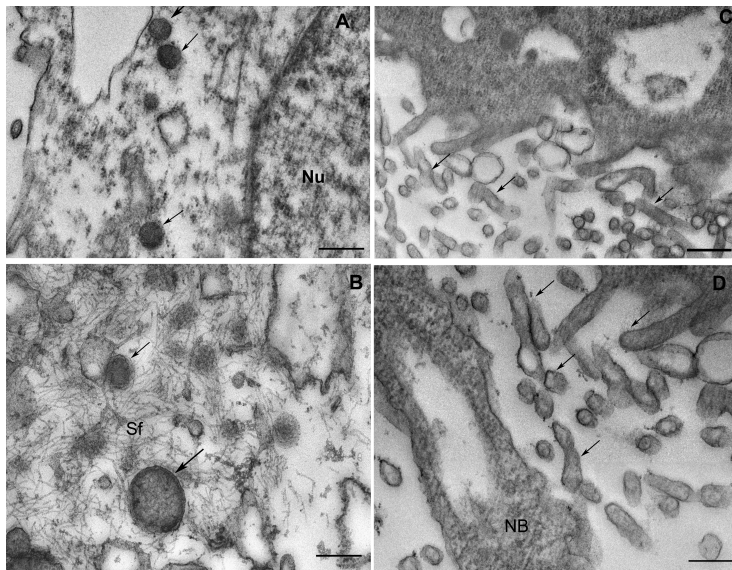


Figure 3. Electron micrographs of cultured PEG cells. A: infected cell 48 h post-infection (pi). The viral inclusions (arrow) were detected inside the cytoplasm. Nucleus (Nu). Bar = 440 nm; B: infected cell 48 h pi; viral inclusions (arrow) and strands forming (Sf) in cellular cytoplasm. Bar = 500 nm; C: infected cell 72 h pi; cytoplasmic vesicles and viral particles (arrows) near the plasma membrane. Bar = 250 nm. D: the viral particles near Negri body-like (NB) structures Bar = 440 nm.

3.5. Genetic identification

Firstly, to identify exactly the virus genotype the fragment of N gene was amplified and sequenced. The bat virus primers including the primers for six genotypes of rabies and rabies-related viruses [Heaton, 1997] were synthesized to identify a virus genome. The amplicon of the expected length was obtained by PCR with the primers 5'-ATG-TAACACCCCTACAATGG-3' and 5'-CAATTTGCACACATTTTGTG-3', and then the nucleotide sequence of amplicon was determined by sequencing. The obtained nucleotide sequence was found to have 95% homology with Irkut strain of bat lyssavirus isolated before from a bat in Eastern Siberia. Earlier Irkut virus strain had been isolated from a dead Greater Tubenosed Bat (*Murina leucogaster*) in Irkutsk [Botvinkin et al., 2003]. The homology level of this nucleotide sequence with European bat lyssavirus 1 (EBLV-1) is substantially less (from 77 to 76% of identity) and even less with EBLV-2, Duvenhage virus and Rabies virus. The complete sequence of N gene of Ozernoe strain determined in our study (GeneBank No FJ905105) has the 93% homology level with Irkut strain, 79% with EBLV-1 strain, 75% with Duvenhage virus, 77% with EBLV-2 and Khujand viruses, 76% with Rabies, Avaran and ABLV viruses, 75% with Lagos, 73% with West Caucasian and 72% with Mokola viruses (Tabl. 2). Since the Ozernoe strain is the first strain of the genotype 8 isolated from a dead human, we have identified its complete genome sequence. For this purpose, the primers for amplification of complete genome fragments were designed by comparison of complete genomes of the Irkut strain and strains of EBLV-1 of the lyssavirus subtype. Then the complete genome sequence of Ozernoe strain was obtained after sequencing and alignment of overlapping fragments (GenBank accession FJ905105). The lengths of each complete viral genome sequences were 11980 bases for Irkut and Ozernoe strains and corresponded to the standard rhabdovirus genome organization. Lyssavirus genome consists of negative-sense, single-stranded RNA that encodes five viral proteins: nucleoprotein N, phosphoprotein P, matrix protein M, glycoprotein G and polymerase L. Comparison with other lyssavirus sequences demonstrates variation in levels of homology: the nucleoprotein was the most conserved, and the phosphoprotein - the most variable genes (Table 2).

The comparison of complete genomes of Ozernoe and Irkut strains confirmed that they are closely related. The complete genome sequence of Ozernoe strain was 92% identical to the complete genome of Irkut strain, 77-78% to the EBLV-1 genome, and 75% to the EBLV-2 genome. Moreover, the virus proteins sequences are more homologous than the corresponding genes. For example, the N and L genes of Ozernoe strain are 92% identical to Irkut strain sequences, as well as 79% and 77%, respectively, to EBLV-1. At the same time, the corresponding nucleoprotein and polymerase sequences have 98% and 92% homology. Phosphoproteins were found to show the most striking difference with 95% and 70% homology, respectively. Phylogenetic analysis of complete-genome nucleotide sequences of all lyssavirus genotypes showed that Irkut and Ozernoe strains are located on the same branch of the phylogenetic tree, have a common ancestor and form one cluster.

| Accession, bat lyssavirus | Maximum identity,% | | | | | |
|---------------------------------------|-------------------------|--------|--------|--------|--------|--------|
| | Coding regions of genes | | | | | |
| | Complete genome | N gene | P gene | M gene | G gene | L gene |
| EF614260.1, Irkut | 92% | 93% | 92% | 92 | 91 | 92 |
| EF157976.1, EBLV 1 isolate RV9 | 77% | 79 | 73 | 80 | 74 | 78 |
| EU293120.1, Duvenhage isolate 94286SA | 75% | 77 | 70 | 79 | 72 | 76 |
| EF614259.1, Avaran | 75% | 76 | 69 | 78 | 72 | 75 |
| EF157977.1, EBLV 2 isolate RV1333 | 75% | 77 | 69 | 80 | 72 | 75 |
| EF614261.1, Khujand | 75% | 76 | 69 | 78 | 72 | 75 |
| AF418014.1, Australian bat lyssavirus | 75% | 76 | 68 | 76 | 71 | 74 |
| JQ685919.1, Rabies isolate NJ2262 | 75% | 75 | 68 | 74 | 71 | 75 |
| EU293108.1, Lagos isolate 0406SEN | 75 | 75 | 72 | 72 | 74 | 71 |
| EU293117, Mokola isolate 86100CAM | 73 | 74 | 74 | 73 | 69 | 71 |
| GU170201, Shimoni | 77 | 76 | 83 | 74 | 65 | 72 |
| EF614258.1, West Caucasian bat virus | 70 | 73 | 74 | 73 | 75 | 72 |

Table 2. Comparison of strain Ozernoe homology with other Lyssaviruses.

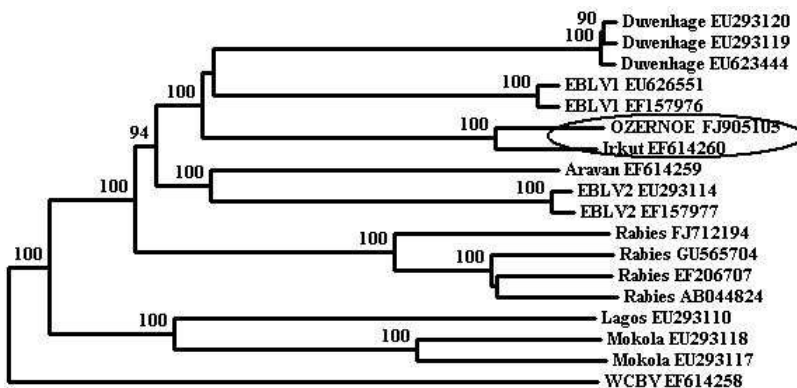


Figure 4. The phylogenetic tree of Lyssaviruses based on complete genome sequences. Virus names are provided according to GenBank records.

4. Discussion

Though human lyssavirus infection cases are rare at Eurasian continent, the minor cases have appeared again and again during the last decades. As a rule, such cases appear unexpectedly, diagnose with delay and end in fatal outcome. For example, the lyssavirus infection case with fatal outcome was described in Scotland in 2003 for the first time in 100 years [Nathwani et al., 2003]. Also, 2 cases of rabies have been confirmed in the United Kingdom in Daubenton's bats (*Myotis daubentonii*): the first in 1996 in Newhaven and the second in September, 2002 in Lancashire; both cases were caused by European bat Lyssavirus (EBLV) type 2a [Whitby et al., 2000; Johnson et al., 2002]. In Europe 3 human deaths from rabies caused by EBLV have been reported [Lumio et al., 1986; Roine et al., 1988; Rabies Bulletin Europe, 1987]. One can say that at present epizootic foci of Lyssaviruses are active and under certain conditions on epidemiological situations the lyssavirus infection cases could take place.

In our study we have shown the first fatal case of lyssavirus infection in Siberia and Russian Far East. The data of epidemiological anamnesis (the patient's underlip was wounded by bat), clinical picture of infection (hypersalivation, choking, baryphonia, acute meningoencephalitis) as well as the virlogical, morphological and molecular genetic data have given the evidence that this case belonged to lyssavirus infection. The brief description of this case was presented earlier in the Journal "Rabies Bulletin Europe" [Leonova et al., 2009].

We have paid attention to the short incubation period (4 weeks), rapid infection development and fast (in 10 days) fatal outcome. First of all, such infection development could be associated with injury localization (head). Thus, the infection fatal case described in Scotland and caused by EBLV-2 was attributed with the bite of patient's finger. The incubation period lasted 19 weeks and fatal outcome came in 14 days after the beginning of disease [Nathwani et al., 2003]. Another fatal case of human rabies caused by Duvenhage bat lyssavirus in Kenya has also indicated about the significance of injury localization [van Thiel et al., 2009]. After the contact with bat the patient has pointed to the small double parallel bleeding wounds at right part of the nose. Though the wounds were disinfected (rinsed with water and soap and treated with alcohol), the patient has got ill in short incubation period (23 days) and died at 20th day of the disease in spite of intensive therapy.

The mother of patient Zh. said that the underlip of her daughter had two typical parallel scratches that were made by bat with the anterior teeth. It means that the saliva of infected animal was in the wound. It should be noted that the appearance of the drops of blood indicated blood vessel damage in dermal layer. But the patients could be mistaken during the contact with bat and told about scratching with leg claws which couldn't form double strip (the bat leg has only one claw) in contrast to skin damage by teeth. The character of skin damage by anterior teeth in a form of double strip should always be the fact of possible virus injection with bat saliva into human blood and requires the drastic measures for the rabies infection prevention.

Therefore, such head injury followed by the vessel damage is considered to have the third severity level which requires the introduction of antirabic immunoglobulin around the

wound as well as a specific vaccination regardless the time of antirabic treatment seeking according to the recent criteria of World Health Organization (WHO) Expert Consultation on Rabies. Despite the wound on the underlip made by bat the patient was not vaccinated against rabies as a preventive measure. Representatives of the health care service in the Primorye Territory did not expect that an accidental contact of a human with bat would cause a typical rabies clinical picture.

The evidence of crossimmunity between classical rabies virus of genotype 1 and Lyssaviruses of genotypes 5 and 6 (EBLV types 1 and 2) was obtained; however, definitive proof of cross-protection is lacking [Badrane et al., 2001]. In spite of this fact, we are sure that in cases of possible infection the emergency vaccinal prevention against the rabies should be carried out. About this suggestion the IIFT results of blood sera of patient triply vaccinated against rabies could indicate because they demonstrated the high levels of sera specificity to Ozer-noe strain antigen. Moreover, it is known that human diploid cells vaccine protects against classic rabies virus strains and Duvenhage virus, but not Mokola virus and Lagos bat virus; Duvenhage virus is neutralized by RIG, but Mokola and Lagos bat viruses are not [Fekadu et al., 1988; Hanlon et al., 2001]. So, based on the cases described above the vaccine against classic rabies could be used for disease prevention caused not only by rabies virus (genotype 1) but by EBLV (types 1 and 2) and Duvenhage virus. Apparently, it could be attributed to fact that Lyssavirus species segregate into two phylogroups. Phylogroup 1 includes Rabies virus (RABV), Duvenhage virus (DUVV), European bat lyssaviruses, type 1 and 2 (EBLV-1 and 2, respectively), and Australian bat lyssavirus (ABLV). Also, Aravan virus (ARAV), Khujand virus (KHUV) and Irkut virus (IRKV) cross-react serologically with the members of phylogroup 1. Phylogroup 2 includes Lagos bat virus (LBV), Mokola virus (MOKV) and Shimon bat virus (SHIBV). West Caucasian bat virus (WCBV) does not cross-react serologically with any of the two phylogroups (http://www.who-rabies-bulletin.org/about_rabies/classification.aspx). Certainly, the exact experimental proofs of cross-reacting protection between different Lyssavirus genetic variants should be known to general practitioners to make rapid and correct decision about vaccinal prevention of rabies infection of different etiology. Especially, it is very important in cases with peripheral localization of injury place when a lot of time is available for virus elimination with specific antibodies after patient's vaccination.

Unfortunately, the bat species was not identified, because the killed bat was tortured by a dog. The residents of Ozer-noe said that dog had died one month later. The dog, as the bat, was not examined. Other cases indicating a spread of the virus were not registered. However, the doctor working in the neighbouring village found a bat at the medical station. The cases when bats enter into houses are not rare and usually not hazardous for human health. At the same time, during the investigation of houses and nonresidential premises in Ozer-noe we did not found any permanent inhabitations of bats. We have suggested that it is possible for bats from nearby forests to enter periodically into the houses.

There are 15 known species of chiropteran in the Far East. The most of them are referred to nonmigratory species; they do not fly far wintering in caves near summer habitats forming large assemblages. Some bat species from southern regions of Primorye Territory spend winters in the balks [Tiunov, 1997].

In Eastern Siberia lyssavirus isolated for the first time from a bat (*Murina leucogaster*) was reported in September, 2002. The bat, which looked healthy, entered into the house in Irkutsk. It was caught and observed. On the tenth day of its observation the symptoms of disease appeared which has resulted in fatal outcome. The virus called Irkut [Botvinkin et al., 2003] was isolated from the brain of the dead animal. During the strain isolation the infected suckling mice had 18 days of the incubation period, and among these mice only one fell ill. At the second passage the incubation period varied from 9 to 18 days. Moreover, it should be noted that the bat infected with Irkut strain wounded the girl, but the illness did not develop due to the timely vaccination against rabies.

Both cases in Irkutsk and Primorye Territory confirm that usually sick animals enter into human dwellings. First of all such animals are of a special danger and require to take measures which protect people from the possible accidental contacts with them. Other cases of lyssavirus infection in Europe reported by Botvinkin et al. (2003) look very similar to these ones.

Unfortunately, the final diagnosis in studied case of infection was stated postmortem. The isolation of Ozernoe strain revealed the following facts to pay attention to: a short incubation period up to 6-7 days; the examined suckling mice of a mouse family fell ill at the same time. If the suckling mice were challenged intracerebrally, the virus titre in the brain of the dead patient was evaluated as 3.7 lg LD₅₀. In the first passage the titre of Ozernoe strain in the mice challenged intracerebrally reached 6 lg LD₅₀. Haemagglutinins were found not only in brain of the infected mice, but also in the brain of the dead patient. These data indicate a high virus concentration which caused profound brain damages and the overall visceral injury followed by impairment of vital functions and resulted in the imminent fatal outcome. The postmortem analysis indicated the changes characteristic for rabies: extensive destructive changes of neurons, formation of many neuronophagic nodules like "rabies nodules", an evident spongy endema of the medullary substance. At the same time, a clearly defined inflammatory reaction around blood vessels was not found. This fact together with the found changes in lymphoid organs indicated the immunodeficiency state, which was undoubtedly associated with the virus infection.

The presence of extracellular viral particles with morphology similar to the structures of Rabies virus on cell surface membranes and spreads forming the electron-dense substance in cellular cytoplasm were revealed during the ultrastructural study. Extracellular viral particles in the environment were distinctly observed and had the morphological signs typical for the group of enveloped viruses with spikes on the surfaces [Iseni, 1998]. The oval and dense bodies (with diameter about 2550 nm) were determined in cytoplasm and mainly in extracellular environment of PEG cells culture infected by strain Ozernoe. These structures were described earlier as Negri bodies in neurons infected by Rabies virus [Velandia et al., 2007].

To identify exactly the virus genotype the fragment of N gene was amplified and sequenced. Moreover, the search for homologous sequences in GeneBank using BLAST program has given the absolute evidence that the closest relative of Ozernoe strain is Irkut strain isolated earlier from the bat in Eastern Siberia. Since the Ozernoe strain is the first strain of the genotype 8 isolated from a dead human, we have determined its complete ge-

nome sequence. The primers for amplification of genome fragments were designed by comparison of Irkut strain complete genome and EBLV-1 strains of the lyssavirus subtype. The comparison of complete genomes sequences of Ozernoe and Irkut strains confirmed that they are closely related. The virus proteins are more homologous than the corresponding genes. For example, N and L genes of Ozernoe strain are 92% identical to Irkut strains, as well as 79% and 77% to EBLV-1, respectively. At the same time, the corresponding nucleoprotein and polymerase have 98% and 92% homology, and the phosphoproteins show the most striking difference with 95% and 70% homology, respectively.

Irkut and Ozernoe strains are located on the same branch of the phylogenetic tree and form one cluster. The divergence time was estimated to be about 650 years that was calculated upon the rate of evolution within the range from 1.5×10^{-4} to 4.3×10^{-4} dS/site/year [Badrane, Tordo, 2001; Hughes, 2008]. It is interesting to note that Irkut and Ozernoe strains are so closely related despite of their divergence time and distance between their isolation places (about 3,000 km).

So we have demonstrated a real possibility of hazardous lyssavirus infection occurrence in cases when humans accidentally meet chiropteran. This is the first confirmed fatal case of lyssavirus infection on the territory of the Asian continent.

5. Conclusion

The clinical and epidemiological characteristics of fatal human case of lyssavirus infection identified for the first time in the Asian part of Russia were provided. The evidence that this case belongs to Lyssavirus infection in the terms of etiology was obtained based on the data of epidemiological anamnesis, clinical picture of infection as well as the virological, morphological, and molecular genetic studies. The pathologic diagnosis was the acute stage of meningoencephalitis as underlying disease with complications of edema, swelling and dislocation of brain, the formation of neuronophagic nodules like "rabies nodules" mainly in the subcortical brain as well as bilateral hypostatic pneumonia and parenchymatous degeneration of myocardium, liver and kidney. The study by electron microscopy revealed that the viral particles of 100 nm in diameter could also be associated with the vesicles close to the endoplasmic reticulum or Golgi apparatus. The complete genome sequence of Ozernoe strain is 92% identical to the complete genome of Irkut strain and 77-78% to EBLV-1 genome. The phylogenetic analysis based on the complete genome sequences revealed that Ozernoe strain, isolated from the brain of the dead patient, and Irkut strain, isolated in Irkutsk from the brain of a bat, are located on the same branch of the phylogenetic tree and have the common ancestor. So the real possibility of serious Lyssavirus infection in cases when people have accidentally encountered with chiropteran was demonstrated.

This case has ended in fatal outcome because of the fact that doctors have never registered patients with a lyssavirus infection in the Far East before. Therefore, it was difficult to make the right decision for emergency vaccination against rabies after the accident as it is usually

done in the cases of classical rabies. The exact diagnosis was not get, the clinical course of infection was rapid and following remedial actions have been unsuccessful.

Acknowledgements

The authors thank the infectious disease specialists, neurologists from clinical hospitals of Primorsky Krai, actively involved in clinical and epidemiological description of the case.

This work was supported by Grant ISTC N° 4006.

Author details

Galina N. Leonova¹, Larisa M. Somova¹, Sergei I. Belikov², Il'ya G. Kondratov², Natalya G. Plekhova¹, Natalya V. Krylova¹, Elena V. Pavlenko¹, Mikhail P. Tiunov³ and Sergey E. Tkachev⁴

1 Institute of Epidemiology and Microbiology, Siberian Branch of the Russian Academy of Medical Sciences, Vladivostok, Russia

2 Limnological Institute, Siberian Branch of the Russian Academy of Sciences, Irkutsk, Russia

3 Biology-soil Institute, Far Eastern Branch of Russian Academy of Sciences, Vladivostok, Russia

4 Institute of Chemical Biology and Fundamental Medicine, Siberian Branch of the Russian Academy of Sciences, Novosibirsk, Russia

References

- [1] Badrane, H., & Tordo, N. (2001). Host switching in Lyssavirus history from the Chiroptera to the Carnivora orders. *J. Virol. Sep.*, 75(17), 8096-104.
- [2] Badrane, H., Bahloul, C., Perrin, P., & Tordo, N. (2001). Evidence of two lyssavirus phylogroups with distinct pathogenicity and immunogenicity. *J. Virol.*, 75, 3268-76.
- [3] Botvinkin, A. D., Kuzmin, I. V., & Rybin, S. N. (1996). The unusual bat lyssavirus Aravan from Central Asia. *Myotis.*, 34, 101-4.
- [4] Botvinkin, A. D., Poleschuk, E. M., Kuzmin, I. V., Borisova, T. I., Gazaryan, S. V., Yager, P., & Rupprecht, C. E. (2003). Novel lyssavirus isolated from bats in Russia. *Emerg. Inf. Dis.*, 9, 1623-1625.

- [5] Botvinkin, A. D., Selnicova, O. P., Antonova, L. A., et al. (2005). Human Rabies case caused from a bat bite in Ukraine. *Rab.Bull.Europe.*, p. 3.
- [6] Boulger, L. R., & Porterfield, J. S. (1958). Isolation of a virus from Nigerian fruit bats. *Trans. R. Soc. Trop. Med. Hyg.*, 52, 421-4.
- [7] Bourhy, H., Kissi, B., Lafon, M., Sacramento, D., & Tordo, N. (1992). Antigenic and molecular characterization of bat rabies virus in Europe. *J Clin Microbiol.*, 30, 2419-26.
- [8] Rab, Bull., & Europe, . (2008). (1-4), 1-4.
- [9] Familusi, J. B., Osunkoya, B. O., Moore, D. L., Kemp, G. E., & Fabiyi, A. (1972). A fatal human infection with Mokola virus. *Am. J. Trop. Med. Hyg.*, 21, 959-63.
- [10] Fekadu, M., Shaddock, J. H., Sanderlin, D. W., & Smith, J. S. (1988). Efficacy of rabies vaccines against Duvenhage virus isolated from European house bats (*Eptesicus serotinus*), classic rabies and rabies-related viruses. *Vaccine*, 6, 533-539.
- [11] Felsenstein, J. (1985). Phylogenies and the comparative method". *American Naturalist*, 125, 1-15.
- [12] Fraser, G. C., Hooper, P. T., Lunt, R. A., Gould, A. R., Gleeson, L. J., Hyatt, A. D., Russell, G. M., & Kattenbelt, J. A. (1996). Encephalitis caused by a lyssavirus in fruit bats in Australia. *Emerg. Infect. Dis.*, 2, 327-31.
- [13] Fooks, A. R., Mc Elhinney, L. M., Pounder, D. J., et al. (2003). Case report isolation of a European bad lyssavirus type-2a from a fatal Human case of Rabies Encephalitis. *J. Med. Virol.*;71, 2(2), 281-289.
- [14] Gribencha S.V.(2008). Rabies. In: Lvov D.K., editor. *Meditinskaya Virusologia (Medical Virology)* [in Russian]. Moscow: "Med. Inform. Agentstvo"; 586-594.
- [15] Hanlon, C. A., De Mattos, C. A., De Mattos, C. C., Niezgoda, M., Hooper, D. C., et al. (2001). Experimental utility of rabies virus-neutralizing human monoclonal antibodies in post-exposure prophylaxis. *Vaccine*, 19, 3834-3842.
- [16] Heaton, P., Johnstone, P., Mc Elhinney, L., Cowley, R., O'Sullivan, E., & Whitby, J. (1997). Heminested PCR assay for detection of six genotypes of rabies and rabies related viruses. *J. Clin. Microbiol.*, 35, 2762-6.
- [17] Hillis, D. M., & Bull, J. J. (1993). An empirical test of bootstrapping as a method for assessing confidence in phylogenetic analysis. *Systematic Biology*, 42, 182-192.
- [18] Hughes, G. J. A., reassessment, of., the, emergence., time, of., European, bat., & lyssavirus, type. . (2008). *Infect. Genet. Evol.*, 8, 820-824.
- [19] Iseni, F., Barge, A., Baudin, F., Blondel, D., & Ruigrok, R. W. H. (1998). Characterization of rabies virus nucleocapsids and recombinant nucleocapsid-like structures. *J. Gen. Virol.*, 79, 2909-2919.

- [20] Ito, S., & Karnovsky, M. J. (1968). Formaldehyde-glutaraldehyde fixatives containing trinitrocompounds. *J. Cell Biol.*, 39:168.
- [21] Johnson, N., Selden, D., Parsons, G., & Fooks, A. R. (2002). European bat lyssavirus type 2 in a bat in Lancashire. *Vet. Rec.*, 151, 455-6.
- [22] Kemp, G. E., Causey, O. R., Moore, D. L., Odelola, A., & Fabiyi, A. (1972). Mokola virus. Further studies on IBAN 27377, a new rabies-related etiologic agent of zoonosis in Nigeria. *Am. J. Trop. Med. Hyg.*, 21, 356-9.
- [23] Kimura, M. (1980). A simple method for estimating evolutionary rates of base substitutions through comparative studies of nucleotide sequences. *Journal of Molecular Evolution*, 16, 111-120.
- [24] King, A. A., Meredith, C. D., & Thomson, G. R. (1994). The biology of Southern African Lyssavirus variants. In: Rupprecht C.E., Dietzschold B., Koprowski H., editors. *Lyssaviruses*. Berlin:Springer-Verlag, 267-295.
- [25] Kuzmin, I. V., Botvinkin, A. D., Rybin, S. N., & Bayaliev, A. B. (1992). Lyssavirus with usual antigenic structure isolated from bat in southern Kyrgyzstan. *Vopr. Virusol.*, 5-6:256-259.
- [26] Kuzmin, I. V., Botvinkin, A. D., & Khabilov, T. K. (2001). The lyssavirus was isolated from a whiskered bat in northern Tajikistan. *Plecotus et al.*, 4, 75-81.
- [27] Kuzmin, I. V., Hughes, G. J., Botvinkin, A. D., et al. (2005). Phylogenetic relationships of Irkut and West Caucasian bat viruses within the Lyssavirus genus and suggested quantitative criteria based on the N gene sequence for lyssavirus genotype definition. *Virus Res.*, 111, 1(1), 28-43.
- [28] Kuzmin I.V., Wu Xianfu, Tordo Noel, Rupprecht C.E.(2008). Complete genomes of Aravan, Khujand, Irkut and West Caucasian bat viruses, with special attention to the polymerase gene and non-coding region. *Virus Res.*, 136, 81-90.
- [29] Leonova, G. N., Belikov, S. I., Kondratov, I. G., Krylova, N. V., Pavlenko, E. V., Romanova, E. V., Chentsova, I. V., & Petukhova, S. A. (2009). A fatal case of bat lyssavirus infection in Primorye Territory of the Russian Far East. *J. "Rabies-Bulletin-Europe" Information Surveillance Report December 2009.*, 33(4-October)
- [30] Lumio, J., Hillbom, M., Roine, R., Ketonen, L., Haltia, M., Valle, M., Neuvonen, E., & Lähdevirta, J. (1986). Human rabies of bat origin in Europe. *Lancet.*, 1:378.
- [31] Mc Call, J. M., Epstein, J. H., Neill, A. S., Heel, K., Field, H., Barret, J., Smith, G. A., Selvey, L. A., Rodwell, B., & Lunt, R. (2000). Potential exposure to Australian bat lyssavirus, Queensland, 1996-1999. *Emerg. Infect. Dis.*, 6, 259-264.
- [32] Meredith, C. D., Rossouw, A. P., & Koch, H. V. P. (1971). An unusual case of human rabies thought to be chiropteran origin. *S. Afr. Med. J.*, 45, 767-769.

- [33] Nathwani, D., Mc Intyre, P. G., White, K., Shearer, A. J., Reynolds, N., Walker, D., Orange, G. V., & Fooks, A. R. (2003). Fatal Human Rabies Caused by European Bat Lyssavirus Type 2a Infection in Scotland. *Clin. Inf. Dis.*, 37, 598-601.
- [34] Pearse A.G.E.(1968). *Histochemistry, theoretical and applied*. 3rd edn., Churchill Livingstone, London, 660.
- [35] Pieter-Paul, A. M., van Thiel, Rob. M. A., de Bie, Filip., Eftimov, Robert., Tepaske, Hans. L., Zaaijer, Gerard. J. J., van Doornum, Martin., Schutten, Albert. D. M. E., Osterhaus, Charles. B. L. M., Majoie, Eleonora., Aronica, Christine., Fehlner-Gardiner, Alex. I., Wandeler, Piet. A., & Kager, . (2009). Fatal Human Rabies due to Duvenhage Virus from a Bat in Kenya: Failure of Treatment with Coma-Induction, Ketamine, and Antiviral Drugs www.plosntds.orgJuly, e428., 3(7)
- [36] Roine, R. O., Hillbom, M., Valle, M., et al. (1988). Fatal encephalitis caused by a bat-borne rabies related virus. *Brain*, 111, 1505-16.
- [37] Schneider, L. G., & Cox, J. H. (1994). Bat lyssaviruses in Europe. In: Rupprecht C.E., Dietzschold B., Koprowski H., editors. *Lyssaviruses*. Berlin: Springer-Verlag, 207-218.
- [38] Selimov, M. A., Tatarov, A. G., Botvinkin, A. D., Klueva, E. V., Kulikova, L. G., & Khismatullina, N. A. (1989). Rabies-related Yuli virus; identification with a panel of monoclonal antibodies. *Acta Virol.*, 33, 542-545.
- [39] Selimov, M. A., Smekhov, A. M., Antonova, L. A., Shablovskaya, E. A., King, A. A., & Kulikova, L. G. (1991). New strains of rabies-related viruses isolated from bats in the Ukraine. *Acta Virol.*, 35, 226-231.
- [40] Shaw, K. L., Lindemann, D., Mulligan, M. J., & Goepfert, P. A. (2003). Foamy virus envelope glycoprotein is sufficient for particle budding and release. *J. Virol.*, 77, 4(4), 2338-2348.
- [41] Shope, R. E., Murphy, F. A., Harrison, A. K., Causey, O. R., Kemp, G. E., Simpson, D. I., & Moore, D. L. (1970). Two African viruses serologically and morphologically related to rabies virus. *J. Virol.*, 6, 690-692.
- [42] Sureau, P., Tignor, G. H., & Smith, A. L. (1980). Antigenic characterization of the Bangui strain (ANCB 672d) of Lagos bat. *Ann. Virol.*, 131, 25-32.
- [43] Swofford, D. L., Waddell, P. J., Huelsenbeck, J. P., Foster, P. G., Lewis, P. O., & Rogers, J. S. (2001). Bias in phylogenetic estimation and its relevance to the choice between parsimony and likelihood methods. *Syst. Biol.*, 50(4), 525-39.
- [44] Tajima, E., & Nei, M. (1984). Estimation of evolutionary distances between nucleotide sequences. *Mol. Biol. Evol.*, 1, 269-285.
- [45] Tiunov M.P.(1997). *Rukokrylye Dalnego Vostoka (Chiropters of the Russian Far East) [in Russian]*. Vladivostok: "Dalnauka", 126 p.
- [46] Van der Merwe, M. (1982). Bats as vectors of rabies. *S. Afr. J. Sci.*, 78, 421-422.

- [47] Velandia, M. L., Perez-Castro, R., Hurtado, H., & Castellanos, J. E. (2007). Ultrastructural description of rabies virus infection in cultured sensory neurons. *Mem. Inst. Oswaldo Cruz.*, Rio de Janeiro, , 102(4), 441-447.
- [48] Warrell, M. J., & Warrell, D. A. (2004). Rabies and other lyssavirus diseases. *Lancet* , 363, 959-969.
- [49] Weekley, B. (1975). *Electron Microscopy for Beginners* [Russian translation], Moscow: "Mir", 320 p.
- [50] WHO Expert Consultation on Rabies: first report.(2004). WHO technical report series, N 931: 18.
- [51] Whitby, J. E., Heaton, P. R., Black, E. M., Wooldridge, M., Mc Elhinney, L. M., & Johnstone, P. (2000). First isolation of a rabies-related virus from a Daubenton's bat in the United Kingdom. *Vet Rec.*, , 147, 385-8.
- [52] World Health Organization.(1987). Bat rabies in the USSR. *Rabies Bulletin Europe* , 4, 12-4.